Cardiac MRI Essentials

Hypertrophic cardiomyopathy

- CMR allows assessment of the following features:
  - Anatomical localisation of areas of hypertrophy
  - Quantification of left ventricular size, function, and mass
  - Mitral valve assessment (systolic anterior motion, mitral regurgitation)
  - Flow assessment (LVOT or mid-cavity obstruction)
  - Identifcation of areas of myocardial fibrosis

Apical hypertrophic cardiomyopathy

- Four-chamber view, cine CMR
- Apical hypertrophy
- Characteristic 'ace of spades' (♠) appearance of left ventricular cavity

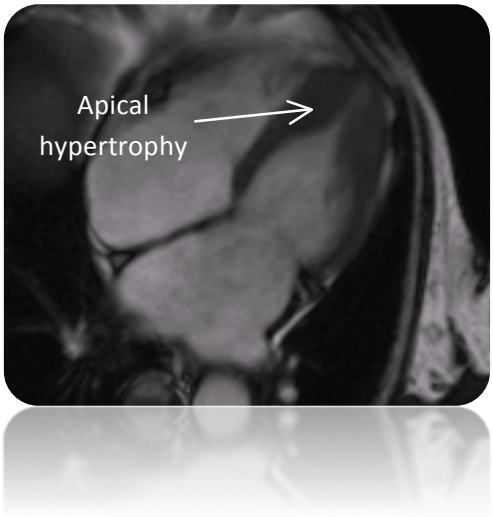

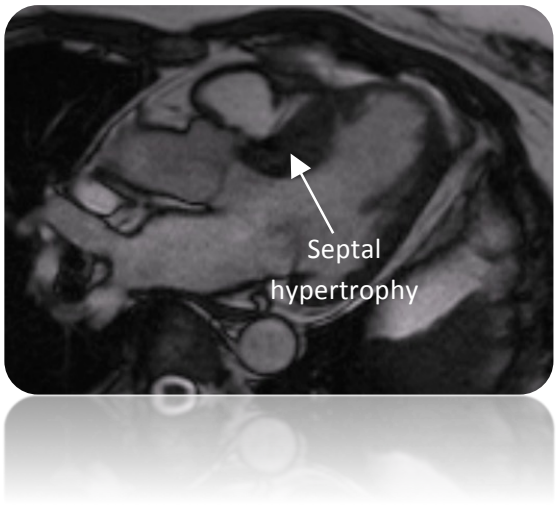

Hypertrophic obstructive cardiomyopathy

- Three-chamber view, cine CMR
- Asymmetrical septal hypertrophy
- Cine CMR also showed systolic anterior motion of mitral valve, and flow acceleration in LVOT

Myocardial fibrosis

- Late gadolinium enhancement imaging
- May identify patchy/diffuse fibrosis in areas of myocardial hypertrophy

How do we use CMR to assess hypertrophic cardiomyopathy?

- Cine CMR
  - Two-, three, four-chamber, LVOT
  - LV short-axis stack
  - Assess morphology, wall thickness, asymmetry
  - LV function, size, and mass
  - Mitral valve—systolic anterior motion
- Tagged cine images (optional)
- Flow CMR
  - In-plane/through-plane
  - Assess LVOT or mid-cavity obstruction
- Late gadolinium enhancement CMR to identify fibrosis.

Further reading

Cardiac magnetic resonance in hypertrophic cardiomyopathy. *J Am Coll Cardiol Img* 2011; **4**: 1123-1137 [click here to access online]